

## The effects of adding platelet rich plasma to fat grafting to rejuvenate the face

Received: 18/06/2022

Accepted: 13/09/2022

Jalal H. Fattah <sup>1\*</sup>

### Abstract

**Background and objective:** Despite refinement in surgical techniques, fat grafting survival is unpredictable, and the resorption rate varies. The objectives of this study were to assess the effects of adding Platelet Rich Plasma (PRP) to fat grafting for facial rejuvenation in terms of longevity of the results, complications, and satisfaction rates.

**Methods:** The thigh or lower abdomen was chosen as a donor site for fat graft harvesting using a 10-cc syringe, then washed with saline, processed by low-speed centrifugation, and then inserted into the face with a 1 mm blunt-ended cannula at several points on several tissue planes. A total of 369 cases treated with autologous fat graft with or without PRP for facial rejuvenation were included in this comparative study. The results were assessed clinically and followed for up to 5 years. Data analysis was done using the statistical package for social science SPSS V. 23.

**Results:** The commonest minor complication was fat absorption (27% in group 1 and 11.9% in group 2), no major complications were reported. Adding PRP to the fat graft decreased the need for second session fat grafting from 31.2% to 15.3%. By adding PRP to fat graft, there was a significant increase in the number of highly satisfied patients (from 63.5% to 80.1%).

**Conclusion:** We believe that adding PRP to autologous fat grafting has several advantages for facial rejuvenation with better long-term results, fewer complications, and better patient and surgeon satisfaction.

**Keywords:** Autologous Fat grafting; PRP; Fat resorption.

### Introduction

Fat addition to facial areas that are atrophied from age or disease can develop a significant improvement in appearance unobtainable by other means.<sup>1</sup>

Adipocytic-derived stem cells (ADCs) are a rich source of regenerative multi-potent cells which may explain fat grafting's success.<sup>2</sup>

Fat is transferred from a donor site to a volume-deficient site.<sup>3</sup> In addition to a volumizing effect, the injected fat has an antiaging effect, neoangiogenesis effect, and improves the cutaneous elasticity.<sup>4</sup>

Fat grafting is preferred by most plastic surgeons since it is available, versatile, non immunogenic, easily harvested, and has

low donor-site morbidity.<sup>5</sup>

Different aesthetic surgeons perform fat grafting differently. There is no worldwide standard for harvesting, preparing, and injecting fat.<sup>6</sup>

In spite of the fact that the procedure of fat grafting has a high success rate in literature, however, variable fat resorption rate leads to the necessity of second fat grafting.<sup>7,8</sup>

The survival rate depends on many variables, but generally on the surgical method. However, despite the excellent surgical technique, fat grafting survival is unpredictable, with the resorption rate varying in the literature from 25% to 80%.<sup>9,10</sup>

<sup>1</sup> Department of Plastic Surgery, College of Medicine, Hawler Medical University, Erbil, Iraq.

Correspondence: [jfattah64@gmail.com](mailto:jfattah64@gmail.com)

Copyright (c) The Author(s) 2022. Open Access. This work is licensed under a [Creative Commons Attribution-NonCommercial-ShareAlike 4.0 International License](https://creativecommons.org/licenses/by-nc-sa/4.0/).

Platelet-rich plasma (PRP) is a rich source of growth factors and platelets.<sup>11,12</sup>

Numerous authors mentioned the advantages and safety of PRP in promoting bone regeneration,<sup>13</sup> wound healing,<sup>14,15</sup> and skin rejuvenation.<sup>16</sup>

We hypothesized that including PRP with fat grafting may be a good way to increase fat survival, making the result more predictable. The aim of this study is to assess the impact of including PRP in fat grafting for facial rejuvenation. The objectives are to find out whether adding PRP to fat graft is beneficial in terms of longevity of the results, complications, and satisfaction rates. To my best knowledge, nobody did this important comparison in our locoregional area.

## Methods

### Patients and Methods:

**Study design:** A comparative study was conducted in CMC and PAR private hospitals in Erbil -Iraq from April 2016 to June 2021. A total of 369 cases (356 female and 13 male) were treated with fat grafts with or without PRP for facial rejuvenation included in this study. The patient's age ranged from 17 to 64 years with an average of 37 years  $\pm$  10.4 SD. All patients were evaluated clinically and photographically before and after the operation. The indications for autologous fat grafting were temporal depression, suborbital depression, cheek, nasolabial fold, lips, mouth angle, chin, and mandibular area or various combinations.

**Exclusion criteria:** Any patient with systemic disease, patients on an anticoagulant, and any patient with psychological disease. Four patients were excluded because of a lack of follow-up, and the remaining 365 cases were included in the study.

### Surgical procedure:

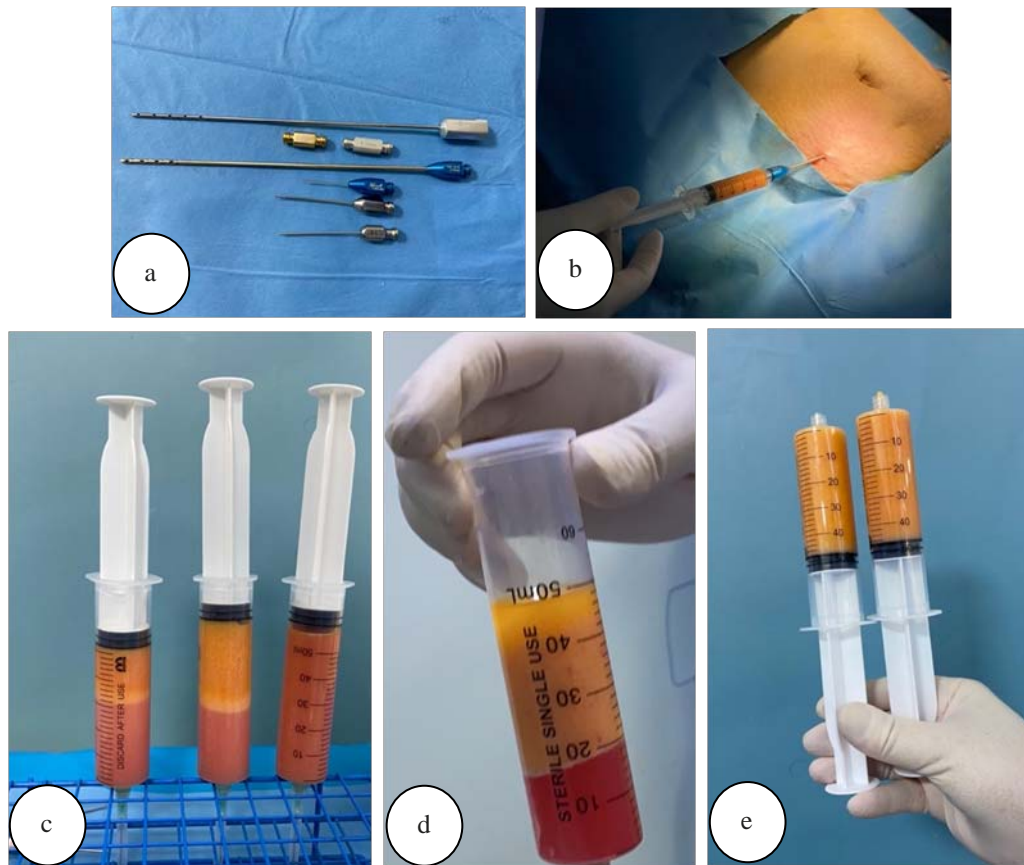
During the pre-operative consultation, past medical history was reviewed. Any patient who is on aspirin is advised to stop it one week prior to fat grafting. Levofloxacin 500 mg tablet started six hours before

fat grafting and for three days after the operation. For patients who had a history of herpes infection, 400 mg of acyclovir were added the first dose six hours before the operation and then two times per day for five days.

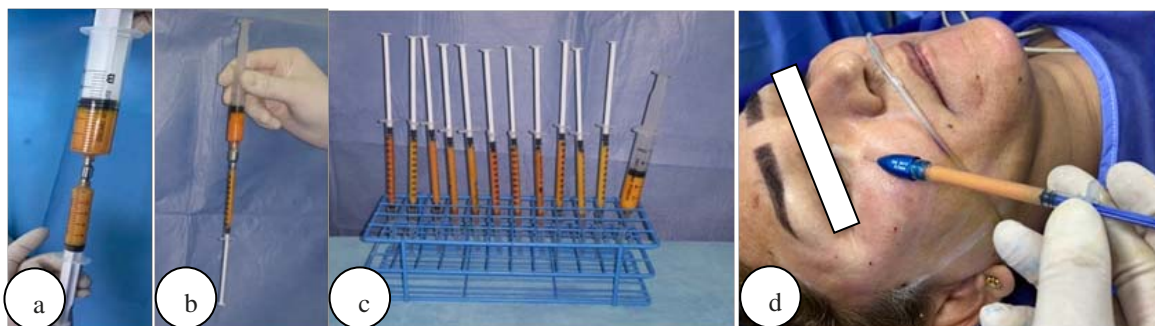Fat is harvested from the thigh or lower abdomen in most of them. Infiltration of the tumescent solution into the donor site was done. Then waiting for 15 minutes to allow adrenaline to have full effect. In most patients, the procedure was done under tumescent anesthesia with sedation. However, general anesthesia was given to only 24 patients.

For fat harvesting, we used a fat harvesting cannula with single or multiple holes 1-2 mm in diameter which is connected to a 10 ml syringe (Figure 1). The fat is aspirated gently with the 10 ml syringe, then washed with normal saline within 50 ml syringe then centrifuged at low speed (1200 rpm) for 3 min. After centrifugation, three layers are visible in the syringe (Figure 1), yellow on the top, blood-colored at the bottom, and pure fat at the center.

The pure fat is transferred into a 10 ml syringe and then to one ml syringes to be ready for fat grafting. Fat grafts are injected in a fan-like manner in multiple entry points into multiple tunnels and multiple tissue planes, using a one ml syringe connected with a blunt fat injection cannula whose external diameter is 0.7 mm for suborbital area and 1mm for other areas (Figure 2).



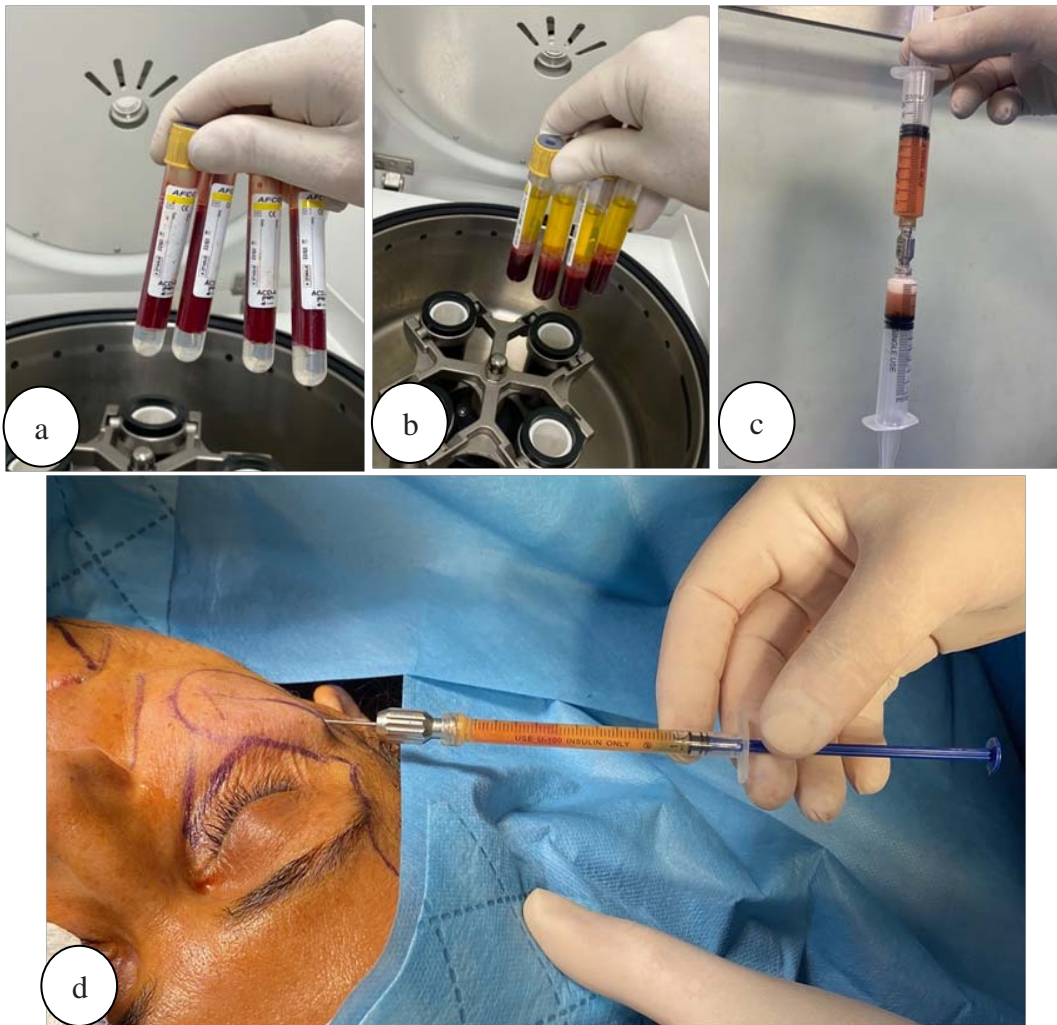
**Figure 1** a- Shows infiltration cannula, connectors, fat harvesting cannula, and fat injection cannula b- Fat harvesting with 10 ml syringe c- Fat washing with saline inside 50 ml syringe d- After centrifugation, three layers are seen in the syringe, yellow destroyed fat on top and blood-colored at the bottom and pure fat at the center. e- Pure fat for injection.



**Figure 2** a,b- The pure fat is transferred into a 10 ml syringe and then to one ml syringes to be ready for fat grafting, c- Fat graft in 1 ml syringes, d- Fat grafts are injected using a one ml syringe connected with a blunt fat injection cannula.

The fat is injected during withdrawal in a minute amount during each pass. Before each injection withdraw the plunger to avoid injecting fat grafts into blood vessels. We do 15% to 20% overcorrection to compensate for possible later fat absorption. Then the face is gently massaged with fingers to obtain smooth contour and avoid irregularity. In the last 176 cases (2<sup>nd</sup> group) PRP was added to the prepared fat in the ratio of 3 ml PRP to 7 ml fat and gently mixed within the syringe then transferred to a one ml syringe for injecting fat and PRP simultaneously in the

previously described manner. For PRP preparation eight ml of patients' blood are put in PRP tubes that contain a special gel separator at the bottom. Centrifugation was done at speed of 3000 rpm for 5 min. After centrifugation the gel will be at the center, red blood cells at the bottom, and plasma on the top that contains platelets and white blood cells which is the PRP, which is then transferred to a new 10 ml syringe then mixed with the prepared fat graft in the ratio of 3ml PRP to 7 ml of fat then mixed gently and transferred to 1 ml syringe to be ready for injection Figure 3.



**Figure 3** a- PRP preparation, before centrifugation the gel is at the bottom of the PRP tube and the whole blood at top, b- after centrifugation for 5 minutes at 3000 rpm, the red cells and debris at the bottom, the gel separator at the middle, and PRP on top of the tube, c- Every three ml of PRP mixed with seven ml of fat d- Fat graft mixed with PRP are injected using 1 cc syringe.



Postoperatively, patients were advised to take a fluid and soft diet, to avoid excessive talking and laughing especially in the first week. Patients were followed up at one week, one month, two months, and four months then yearly and standard photos were taken during the visit. The final results were evaluated by the patients, and the plastic surgeon by comparing pre-and postoperative photos and subjective improvements. The degree of improvement was classified as highly satisfactory, moderately satisfactory, and unsatisfactory. **Ethical considerations:** The study Proposal was approved by the Medical Ethics Committee at the College of Medicine – Hawler Medical University. Informed consent was obtained from all patients.

The author has no conflict of interest. **Statistical analysis:** Data were analyzed using the statistical package for social sciences (SPSS, version 23). The Chi-square test of associates was used to compare proportions. A *P*-value of less or equal to 0.05 was considered statistically significant.

**Results**

Simultaneous fat grafting of the cheek and suborbital area was the commonest indication of fat grafting (109 cases, 57.7%) as seen in Table 1. Fat absorption was the commonest minor complication (27% in group 1 and 11.9% in group 2), fortunately, major complications were reported in our study (Table 2).

**Table 1** Indications of fat grafting in both groups.

Patient group	Indications					<i>P</i> value
	Cheek and suborbital No. (%)	Cheek No. (%)	Suborbital No. (%)	Multiple sites No. (%)	Total No. (%)	
Group 1 Fat graft without PRP	120 (63.5%)	26 (13.8%)	8 (4.2%)	35 (18.5%)	189 (100%)	0.33
Group 2 Fat graft with PRP	117 (66.5)	28 (15.9)	10 (5.7%)	21 (11.9)	176 (100%)	

Multiple sitefat grafting means full facial fat grafting.

**Table 2** Complications encountered.

Complications	Patient group		<i>P</i> value
	Group 1 Fat graft without PRP No. (%)	Group 2 Fat graft with PRP No. (%)	
None	120 (63.5%)	143 (81.3%)	0.003
Edema	7 (3.7%)	5 (2.8%)	
Ecchymosis	5 (2.6%)	2 (1.1%)	
Fat absorption	51 (27%)	21 (11.9%)	
Asymmetry	6 (3.2%)	5 (2.8%)	
Total	189 (100%)	176 (100%)	

Adding PRP to the fat graft decreased the need for second session fat grafting from 31.2% to 15.3% as shown in Table 3.

Fat injection yielded a high satisfaction rate in both groups, however; by adding PRP to fat graft in group 2, the number of

highly satisfied patients was significantly increased (from 63.5% increased to 80.1%) as shown in Table 4.

Similarly adding PRP to fat graft increased the surgeon high satisfaction rate (from 64% to 80.7%) as shown in Table 5.

**Table 3** Number of fat grafting sessions in both groups.

Patient group	Number of fat grafting		Total	P value
	One session No. (%)	Two sessions No. (%)		
Group 1 Fat graft without PRP	130 (68.8%)	59 (31.2%)	189 (100%)	0.001
Group 2 Fat graft with PRP	149 (84.7%)	27 (15.3%)	176 (100%)	

**Table 4** Patient satisfaction rate in both groups.

Patient satisfaction	Patient group		P value
	Group 1 Fat graft without PRP No. (%)	Group 2 Fat graft with PRP No. (%)	
Highly satisfied	120 (63.5%)	141 (80.1%)	0.002
Moderate satisfaction	58 (30.7%)	30 (17%)	
Unsatisfied	11 (5.8%)	5 (2.8%)	
Total	189 (100%)	176 (100%)	

**Table 5** Surgeon satisfaction rate in both groups.

Surgeon satisfaction	Patient group		P value
	Group 1 Fatgraft without PRP No. (%)	Group 2 Fatgraft with PRP No. (%)	
Highly satisfied	121 (64%)	142 (80.7%)	0.002
Moderate satisfaction	61 (32.3%)	31 (17.6%)	
Unsatisfied	7 (3.7%)	3 (1.7%)	
Total	189 (100%)	176 (100%)	

## Discussion

Recognizing the importance of volume loss in facial aging leads to increasing use of fat grafting for facial rejuvenation to give a younger look to the face.<sup>17</sup>

In this study, augmenting the cheek and suborbital area simultaneously was the commonest indication for fat grafting (63.5% in group 1 and 66.5% in group 2) Table 1. This is in agreement with Jason M et al<sup>17</sup> and Xie Y et al.<sup>18</sup> Signs of aging are commonly seen in the mid-face in the form of suborbital hollowness, and flat cheek. Fat grafting can address these aging signs easily.

Generally, fat grafting is a safe procedure, however, minor complications can happen. Fat absorption was the commonest minor complications which was more common in group 1 (27%) in whom PRP was not added to the fat graft versus 11.9% in group 2 in whom PRP was added to the fat graft in the ratio of 0.3 ml PRP to 0.7 ml fat which is statistically significant difference. We can make a conclusion that adding PRP to fat graft is desirable and effective way decrease fat absorption rate and we recommend it in all fat grafting for facial rejuvenation.

This is in agreement with Shinichiro N et al. who showed that adding PRP to fat graft in rats increased the fat survival rates significantly.<sup>19</sup>

PRP is a natural source of platelets and cytokines.<sup>20</sup> Its therapeutic action depends on the release of many growth factors from platelet  $\alpha$  granules.<sup>21</sup> These growth factors like vascular endothelial growth factor, platelet-derived growth factor, insulin-like growth factor, and transforming growth factor  $\beta$  act by enhancing the recruitment and activation of cells responsible for tissue repair, in addition, these growth factors also promote angiogenesis, which facilitates recovery from the ischemia that accompanies fat transfer.<sup>22</sup>

Slight facial edema is a common sequela, but fortunately will be resolved within 3-5 days, however; significant facial edema was seen in 3.7% in group 1 and 2.8% in

group 2 which was treated by head elevation, cold sponges, and prednisolone 5 mg tab. Ecchymosis was seen in frequently, however, it was less in group 2 (2.6% in group 1 decreased to 1.1% in group 2 in whom PRP was added to fat grafting) which resolved within 10 days. Mild facial asymmetry is seen in 3.2% in group 1 and 2.8% in group 2 which may be explained by sleeping more on one side and different blood supplies, it is solved with secondary fat graft.

Rodríguez-Flores et al. compared the histological characteristics of grafted fat with and without PRP in rabbits. They found that when PRP was added, there was more fat survival and less inflammation<sup>23</sup> This may explain less ecchymosis and facial edema by adding PRP to fat graft in group 2.

Infection was not reported in this series in agreement with Kotaro Y and Sydney C.<sup>24</sup> who found that infection is rare in fat grafting to the face. This may be explained by using sterile techniques in fat grafting, giving prophylactic antibiotics, and placing the fat in tiny quantities in multiple tissue planes.

Fortunately, major complication like blindness was not reported in this series. However; Aleksandra S. et al reported a case of acute blindness following a fat graft to the right forehead area due to ocular fat embolism.<sup>25</sup>

To avoid ocular fat embolism, we used a blunt-tipped cannula, initial withdrawal prior to injection, and fat injection during withdrawal using low injection pressure.

Fat grafting yielded a high satisfaction rate in both groups (Figure 4, and 5), however; by adding PRP to fat graft in group 2, the number of highly satisfied patients was significantly increased (from 63.5% increased to 80.1%) as shown in Table 4. This may be explained by better fat survival, less ecchymosis, less oedema, and skin rejuvenating effect of PRP leading to better patient satisfaction (Figure 5).

The main cause of patient dissatisfaction was the volume loss observed in the first

three months which solved with secondary fat grafting about six months after the first fat grafting. Most of the dissatisfied patients were satisfied after the secondary fat grafting.

Our result is in agreement with Jordan G et al,<sup>26</sup> and Tolba M et al,<sup>27</sup> who reported the overall take rate of fat grafting ranging from 50-90%.

### Conclusion

We believe that adding PRP to autologous fat grafting has several advantages for facial rejuvenation with better long-term results, less complications, and better satisfaction.

### Funding

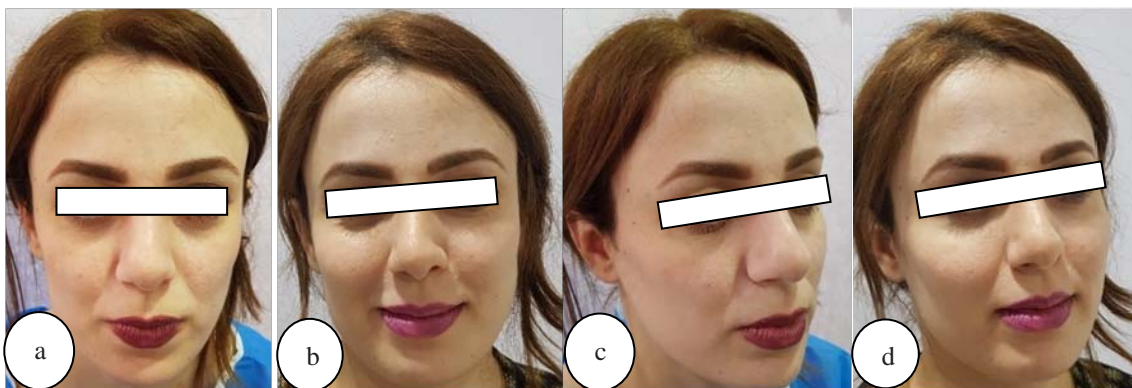Not applicable.

### Competing interests

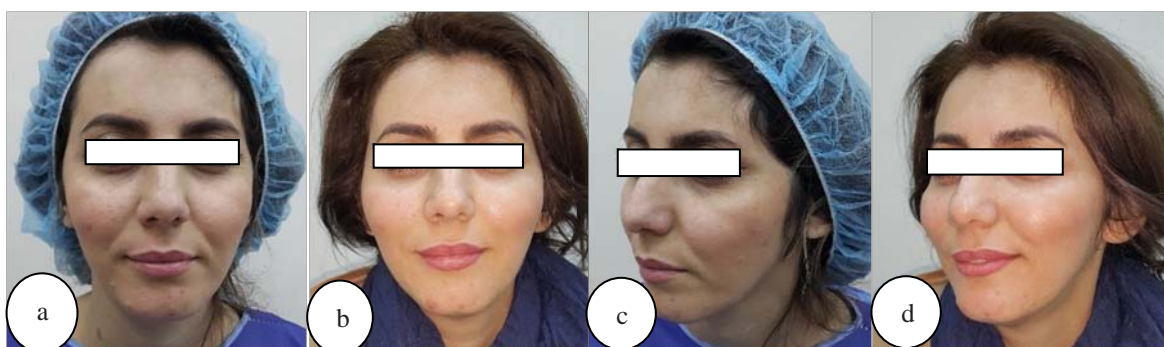The author declares that he has no competing interests.

### References

1. Timothy M, Dino. Facial Fat Grafting: Why, Where, How, and How Much. *Aesth Plast Surg* 2018; 42:1278–97. [DOI:10.1007/s00266-018-1179-x](https://doi.org/10.1007/s00266-018-1179-x)
2. Shidie C, Zhigang H, Jinghong X. Application of adipose-derived stem cells in photoaging: basic science and literature review. *Stem Cell Research & Therapy* 2020; 11:491. [DOI:10.1186/s13287-020-01994-z](https://doi.org/10.1186/s13287-020-01994-z)
3. Lee P. Fat grafting for facial rejuvenation, my preferred approach. *Clinics in plastic Surgery* 2020; 47(1):19–29. [DOI:10.1016/j.cps.2019.08.002](https://doi.org/10.1016/j.cps.2019.08.002)
4. Modarressi A. Platelet Rich Plasma (PRP) Improves Fat Grafting Outcomes. *World J Plast Surg* 2013; 2(1):6–13.



**Figure 4** a,c: Before facial fat grafting. b,d: Three years after one session of facial fat grafting shows good improvement of facial appearance.



**Figure 5** a,c: Before facial fat grafting mixed with PRP. b,d: Four years after one session of facial fat grafting mixed with PRP shows a great improvement in facial appearance and skin brightening.



5. Joshua L, Oliver S, Afshin M. A systematic review of autologous platelet-rich plasma and fat graft preparation methods. *Plast Reconstr Surg Glob Open* 2017; 5:e1596. DOI: [10.1097/GOX.0000000000001596](https://doi.org/10.1097/GOX.0000000000001596)
6. Saad I, Adham F, Iman S. Facial rejuvenation: Serial fat graft transfer. *AJM* 2016; 52:371–6.
7. Stallworth L, Wang D. Fat grafting of the midface. *Facial Plast Surg* 2010; 26(5):369–75. DOI: [10.1055/s-0030-1265020](https://doi.org/10.1055/s-0030-1265020)
8. Francesco S, Nicolo B, Michele G, Eugenio G, Edoardo R. Procedure, applications, and outcomes of autologous fat grafting. *JAMSU* 2017; 20; 49–60. DOI: [10.1016/j.amsu.2017.06.059](https://doi.org/10.1016/j.amsu.2017.06.059)
9. Marten T. Discussion of Shue et al. "Fat Injection: A Systemic Review of Injection Volumes by Facial Subunit. *Aesth Plast Surg* 2018; 42:1271–6. DOI: [10.1007/s00266-018-1168-0](https://doi.org/10.1007/s00266-018-1168-0)
10. Kapil A, Manoj B, Charudatta N, Harshwardhan T, Shilpa S. Autologous Fat Transfer for Esthetic Contouring of Face in Posttraumatic Nonfunctional Maxillofacial Deformities. *Craniofacial Trauma Reconstruction* 2016; 9(2):113–20.
11. Maria S, Arturo C, Ivan S, Josa E, Ignasi B, Luciano R, et al. Autologous platelet-rich plasma for treating chronic wounds. *Cochrane Database Syst Rev* 2016; (5)CD006899. DOI: [10.1002/14651858.CD006899.pub3](https://doi.org/10.1002/14651858.CD006899.pub3)
12. Cohn S, Lockhart E. Autologous platelet-rich plasma: evidence for clinical use. *Curr Opin Hematol.* 2015; 22(6):527–32. DOI: [10.1097/moh.000000000000183](https://doi.org/10.1097/moh.000000000000183)
13. Mooren M, Merckx W, Bronk M, Jansen A, Stoeltinga W. The effect of platelet-rich plasma on early and late bone healing using a mixture of particulate autogenous cancellous bone and Bio-Oss: an experimental study in goats. *Int J Oral Maxillofac Surg* 2010; 39(4):371–8. DOI: [10.1016/j.ijom.2009.12.019](https://doi.org/10.1016/j.ijom.2009.12.019)
14. Villela L, Vera C, Santos G. Evidence on the use of platelet-rich plasma for diabetic ulcer: a systematic review. *Growth Factors* 2010; 28(2):111–6. DOI: [10.3109/08977190903468185](https://doi.org/10.3109/08977190903468185)
15. Lacci M, Dardik A. Platelet-rich plasma: support for its use in wound healing. *Yale J Biol Med* 2010; 83(1):1–9.
16. Shahin A. Platelet-rich plasma in skin rejuvenation. *J Surg Dermatol* 2017; 2(2):61–2. DOI: [10.18282/jds.v2.i2.150](https://doi.org/10.18282/jds.v2.i2.150)
17. Ahmed S, Ibrahim K, Amr N. Fat Injection for Restoration of Facial Volume and Aesthetics Versus Conventional Facelift Surgery. *Egypt J Plast Reconstr Surg* 2019; 43(2):325–9.
18. Xie Y, Zheng N, Li F. An integrated fat grafting technique for cosmetic facial contouring. *J Plast Reconstr Aesthetic Surg* 2010; 63(2):270–6. DOI: [10.1016/j.bjps.2008.11.016](https://doi.org/10.1016/j.bjps.2008.11.016)
19. Shinichiro N, Masayuki I, Megumi T, Kaoru M, Satoko K, Shingo N, et al. Platelet-rich plasma (PRP) promotes survival of fat-grafts in rats. *Ann Plast Surg* 2010; 65(1):101–6. DOI: [10.1097/SAP.0b013e3181b0273c](https://doi.org/10.1097/SAP.0b013e3181b0273c)
20. Martinez-Zapata MJ, Martí-Carvajal AJ, Sola I, Exposito JA, Bolibar I, Rodriguez L, et al. Autologous platelet-rich plasma for treating chronic wounds. *Cochrane Database Syst Rev* 2016; 2016(5):CD006899. DOI: [10.1002/14651858.CD006899.pub3](https://doi.org/10.1002/14651858.CD006899.pub3)
21. Amable R, Carias B, Teixeira V. Platelet-rich plasma preparation for regenerative medicine: optimization and quantification of cytokines and growth factors. *Stem Cell Res Ther* 2013; 4(3):67.
22. Cohn S, Lockhart E. Autologous platelet-rich plasma: evidence for clinical use. *Curr Opin Hematol* 2015; 22(6):527–32. DOI: [10.1097/MOH.000000000000183](https://doi.org/10.1097/MOH.000000000000183)
23. Jordi F, Maria G, Ana V, Jose P, Jesus T. Influence of platelet-rich plasma on the histologic characteristics of the autologous fat graft to the upper lip of rabbits. *Aesthetic Plast Surg* 2011; 35(4):480–6. DOI: [10.1007/s00266-010-9640-5](https://doi.org/10.1007/s00266-010-9640-5)
24. Kotaro Y, Sydney C. Complications of Fat Grafting How They Occur and How to Find, Avoid, and Treat Them. *Clin Plastic Surg* 2015; 42:383–8. DOI: [10.1016/j.cps.2015.04.002](https://doi.org/10.1016/j.cps.2015.04.002)
25. Aleksandra S, Michał O, Ida M, Mariusz S, Małgorzata O. Jan Z. Ocular Complications Following Autologous Fat Injections into Facial Area: Case Report of a Recovery from Visual Loss After Ophthalmic Artery Occlusion and a Review of the Literature. *Aesth Plast Surg* 2017; 41:580–4. DOI: [10.1007/s00266-017-0805-3](https://doi.org/10.1007/s00266-017-0805-3)
26. Jordan G, Alex M, Nayif A, Alain A, Mirko G.A systematic review of the effectiveness and complications of fat grafting in the facial region. *JPRAS Open* 2019; 19:87–97. DOI: [10.1016/j.jpra.2018.12.004](https://doi.org/10.1016/j.jpra.2018.12.004)
27. Tolba M, Nasr M. Initial experience of face augmentation using fat graft-platelet rich plasma mix. *Surg Sci* 2015; 6:489–98. DOI: [10.4236/ss.2015.611071](https://doi.org/10.4236/ss.2015.611071)