

## Sinus floor elevation procedure with immediate implant placement using artificial bone substitutes: a prospective clinical study

Received: 23/10/2010

Accepted: 9/12/2010

Omed I. Shihab\*

### Abstract

**Background and objectives:** This study was designed to evaluate the clinical status of implants placed immediately in lifted maxillary sinus using Resorbable Tissue Replacement (R.T.R.) cone bone substitutes.

**Methods:** Twenty implants were placed in twenty patients in the period between Jan. 2006 and Sept. 2010. Lateral approach, open window method for sinus lift with placement of Resorbable Tissue Replacement Cone bone substitutes were carried out. A 4-6 mm of the bone level was required in the alveolar ridge for primary stability, with sufficient inter-arch space for the prosthesis. All implants were placed in upper molar region simultaneously with sinus lift procedure in conjunction with Tissue Replacement Cone bone substitutes. The implant survival was defined when the prosthesis had been delivered and followed for two years without infection, pain, and mobility after loading.

**Results:** Twenty patients, 13 males and 7 females, with an average age of 41 years old were participated in this study. A total of twenty implants were followed up for two years. Eighteen patients with eighteen implants (90.0%) showed no signs of sinusitis or other complications and the peri-implant health judged to be good with a peri-implant sulcus depth of 2-3mm. Two implants (10%) showed mobility before loading.

**Conclusion:** A good survival rate was observed in implants placed immediately in lifted maxillary sinus using Resorbable Tissue Replacement (R.T.R.) cone bone substitutes.

**Key words:** sinus lifting procedure, immediate implant, bone substitutes

### Introduction

Implant placement in the posterior maxilla can be problematic, because the alveolar process tends to resorb with age and the maxillary sinus becomes larger. Because there is little available bone volume in this region, sinus floor elevation has become an important procedure in peri-implant grafting.<sup>1</sup> The surgical technique of maxillary sinus floor elevation was first published by Boyne in 1980.<sup>2</sup>

Various maxillary sinus floor augmentation techniques have been proposed for managing severe bone loss in the posterior maxilla.<sup>3-7</sup> The sinus lift subantral augmentation procedure is a well accepted technique to treat the loss of vertical bone

height in the posterior maxilla. The surgery is predictable, is not technically demanding, and has greater efficacy in the totally edentulous posterior maxilla. The basic surgical technique involves adequate flap reflection, creating a buccal window osteotomy, reflection of the antral membrane exposing the medial wall, and a loose compaction of the graft.<sup>8</sup> R.T.R. cone is made from  $\beta$  tricalcium phosphate granules coated with a matrix of highly purified collagen fibers of bovine origin, which meet the health and safety requirements recommended by the WHO and the EU. A particulate bone graft material, allogeneic, autogenous, or a combination can be used with immediate implant placement. This procedure has a success rate of about

\*Department of Oral and Maxillofacial Surgery, College of Dentistry, HMU, Erbil, Iraq

90%<sup>9</sup>. To the author knowledge no published papers are available regarding the use of sinus lift procedure with immediate implant placement in Iraqi Kurdistan, accordingly this study was designed to evaluate the success rate of sinus lift procedure with immediate implant placement for patients from Erbil city.

## Methods

In a prospective clinical study twenty patients were underwent sinus lift procedure with immediate implant placement in conjunction with bone substitutes in the period between 2006 and 2010. Panoramic radiographs were taken for all the patients for assessments of the alveolar bone height, the status of the natural teeth and exclusion of any pathology.

### The inclusion criteria were:

- 1- Clinically healthy patients with good oral hygiene
- 2- Alveolar bone ridge height of at least 4mm (required for primary stabilization).
- 3- Patient consent achieved for the procedure
- 4- Adequate inter-arch space for the prosthesis

### Surgical procedure: (Figures 1-9)

1-All patients were operated on under local anesthesia, infiltration technique, (lidocaine 2% with vasoconstrictor 1/80,000, CRISTALIA, Brazilia),

2- The perioral region scrubbed by gauze immersed in Iodine solution. Chlorhexidine 0.12% mouth wash was used to disinfect the oral cavity through gargling for 1 minute

3-The posterior maxillary edentulous area and the maxillary sinus wall were exposed via a full thickness 3 sided mucoperiosteal flap.

4-Bone window osteotomy (6mm diameter) was made using surgical bur (Fissure, DENDIA, A-6800Feldkrich, Germany) in straight hand piece (W&H, Synea HA-43A, Austria) in the lateral wall of the sinus, 6 mm apical to the crest of the ridge to preserve the remained alveolar bone.

5- The sinus membrane was detached by large surgical curette (double ended,

Martin) and the bony window was pushed and rotated horizontally along with sinus membrane elevation to form apical bony wall for the inserted implant. The sinus membrane was elevated for about 6mm.

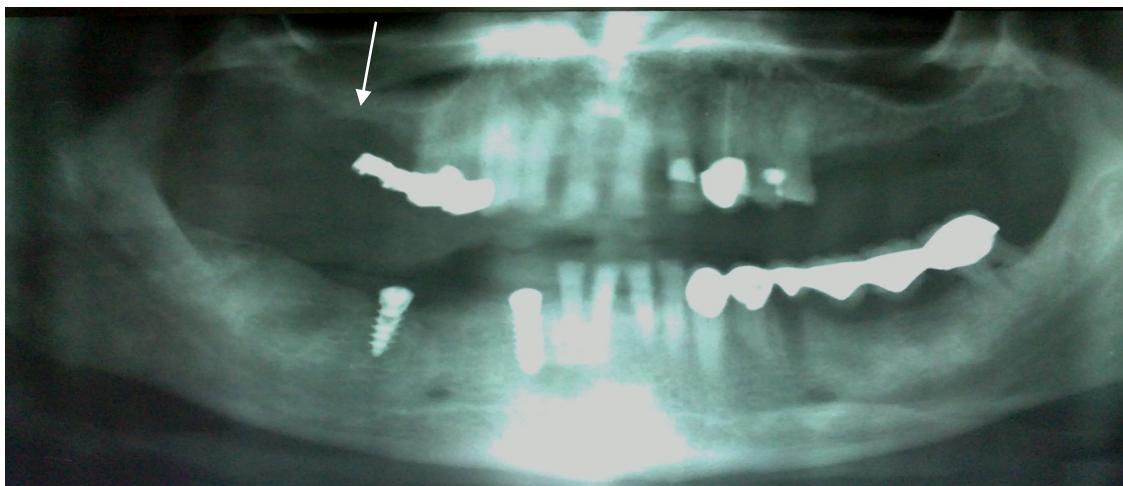
6- The alveolar ridge then drilled by Q-Implant surgical set and the implant bed was prepared. A 4mm width and 12mm length implant (TRINON GmbH, QK) was inserted in the prepared bed to achieve primary stability. Then the area between the floor of the sinus and the lifted membrane and the area around the exposed implant was filled with SEPTODONT R.T.R. cone (Resorbable Tissue Replacement, 400µm macropores size, France) impregnated with normal saline. No membrane was used to cover the lateral window in all of the patients.

7- The mucoperiosteal flap was replaced and sutured by simple interrupted suture technique, using (Black silk suture 3/0, ETHICON SETA, B-1130 Brussels, Belgium)

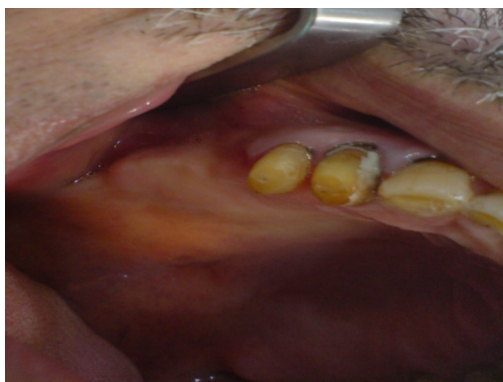8- Antibiotic, Amoxiklave Tab (Ranbaxy, India, 625mg b.d) and Analgesic, NOPAIN Tab (Naproxen 500mg, Jordan, on need) were prescribed for the patients for 5 days. Chlorhexidine 0.12% mouth wash also prescribed for the patients for 3 times per day for 5 days.

9- The suture was removed after 10 days.

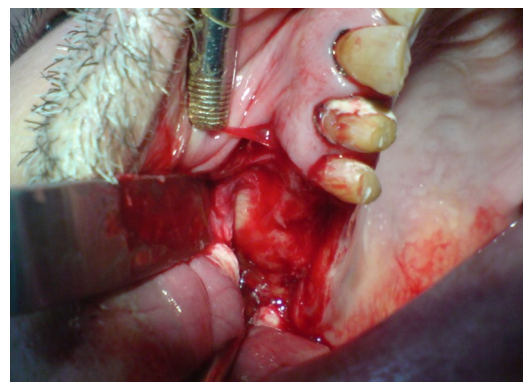
10- Patients were examined clinically (for pain, discomfort, exposure of implant) every month for the first 6 months, and had panoramic radiographs in the 3<sup>rd</sup> and 6<sup>th</sup> months after the operation. After 6 months the implants were exposed by punch technique. The healing screws replaced by gingival former for two weeks duration before the beginning of prosthetic phase. The implant survival was defined when the prosthesis had been delivered and followed for two years without infection, pain, and mobility after loading.



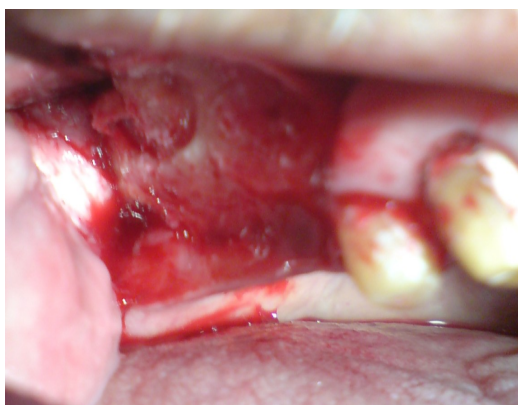**Figure 1:** An OPG view of a patient with deficient vertical bone height



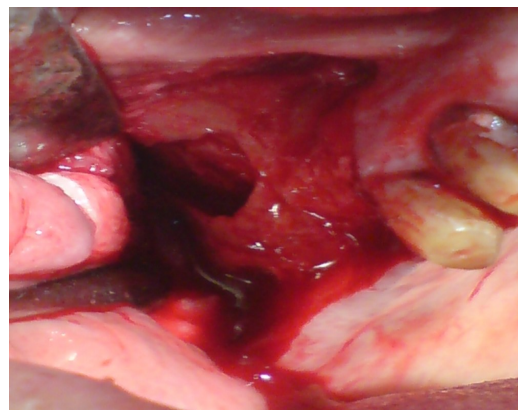
**Figure 2:** Preoperative clinical picture of upper posterior alveolar ridge



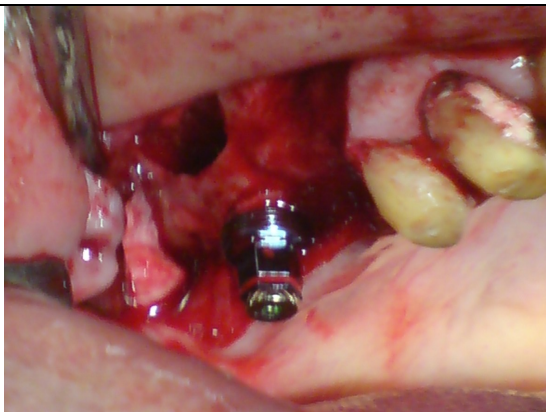
**Figure 3:** A three sided flap was reflected to expose the lateral wall of the sinus



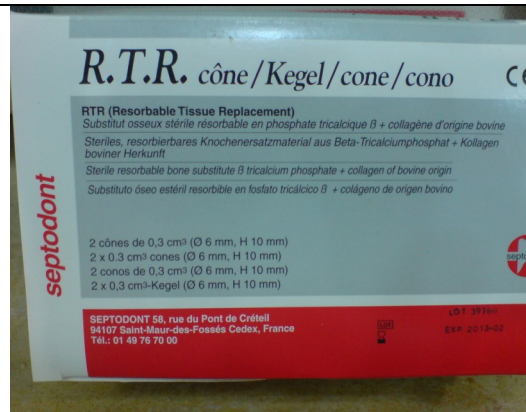**Figure 4:** bony cut was done to outline the window to be opened on the lateral wall of the maxillary sinus



**Figure 5:** The bony window was pushed and rotated horizontally along with sinus membrane elevation



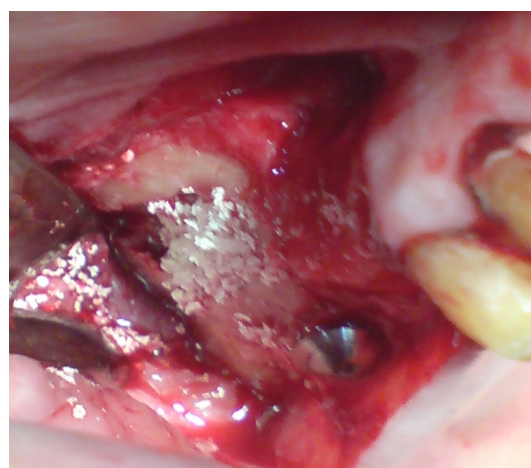
**Figure 6:** Implant was placed in the prepared bed



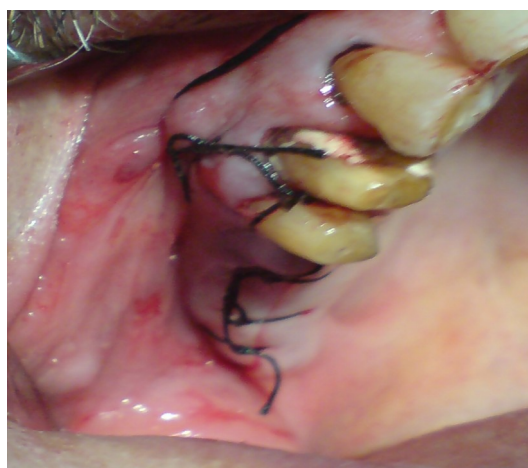**Figure 7:** Showing R.T.R. cone bone substitutes



**Figure 7:** R.T.R. cone after mixing with normal saline



**Figure 8:** R.T.R. cone filled the space created by sinus lift procedure



**Figure 9:** The flap is replaced and sutured by simple interrupted suture technique.



## Results

Twenty clinically healthy patients, 13 males and 7 females, with an average age of 41 years were participated in this study. The patients gender, age, site of implant, infection during healing period and mobility of the implants after 6 months are shown in (Table 1). Eighteen patients with eighteen implants (90%) in the sites of 1st premolar, 2nd premolar and 1st molar showed no signs of sinusitis, mucosal infection and mobility. The peri-implant sulcus depth measured by periodontal probe and ranged from 2-3mm. Two implants (10%) in 2

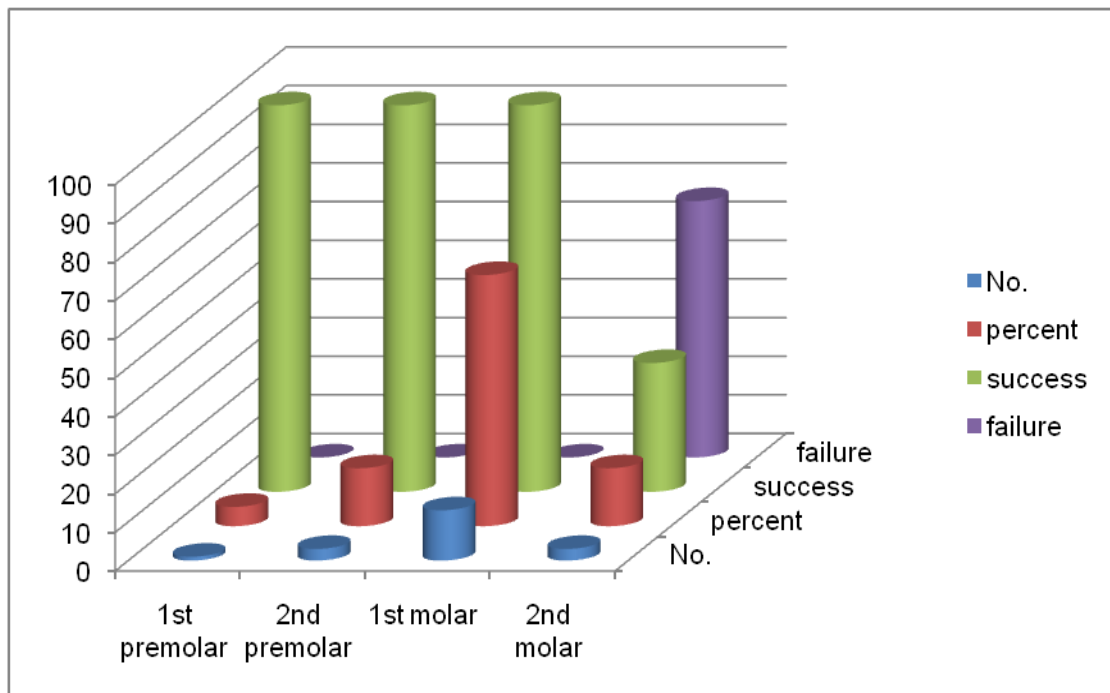
male patients became mobile after the sixth month of insertion, which was an indication of failure of osseointegration. There were no signs of infection other than the mobility. The failure of osseointegration were, in the 2nd molar site, when we tried to replace the healing cap by the gingival former (Figure 10). The 2 patients were treated by traditional bridge prosthesis.

Figures (11 and 12) shows OPG views after 3 and 6 months of operation.

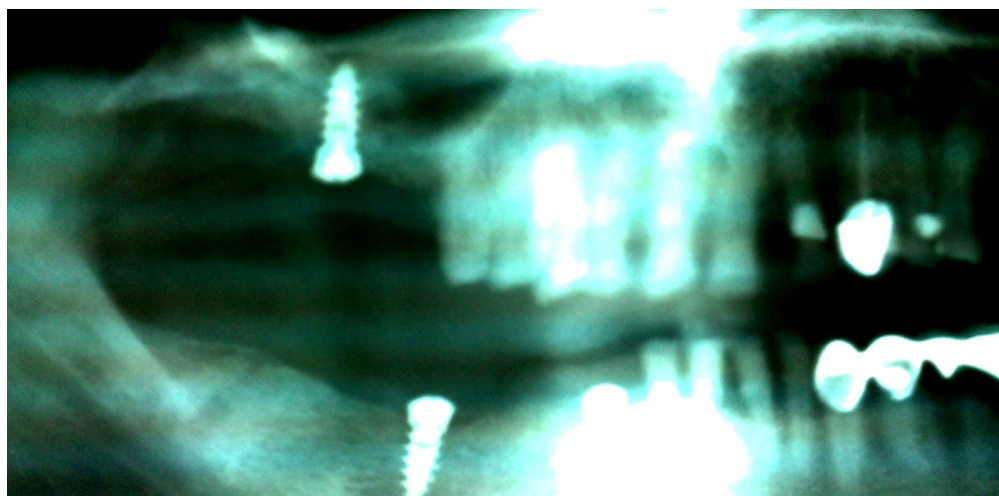
After loading no patient returned back with complaint.

**Table 1:** Patients Gender distribution, age, site of implant, infection and mobility

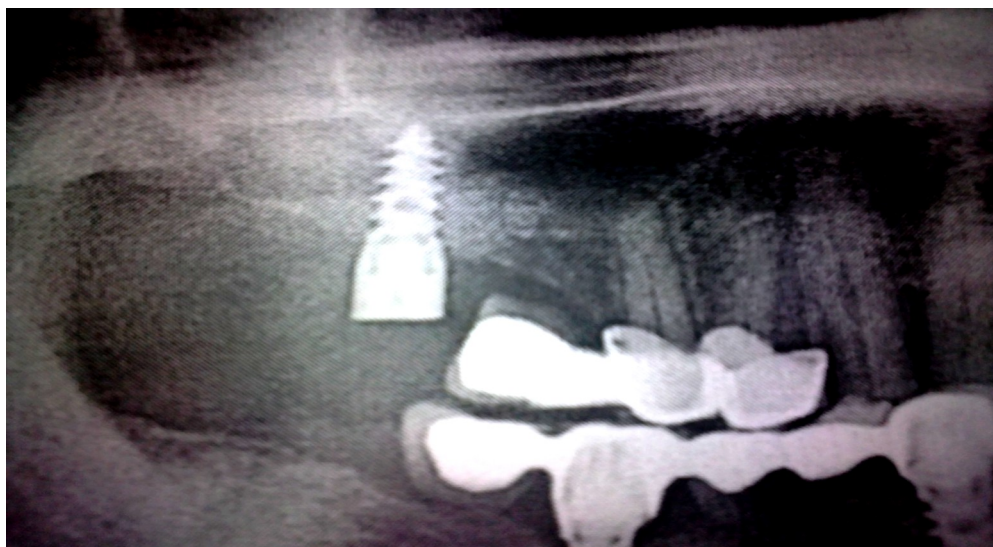
Patient No.	Gender		Age (years)	Site of implant	Infection	Mobility after 6 months
	Male	Female				
1	*		53	1 <sup>st</sup> molar	Nil	
2	*		42	1 <sup>st</sup> molar	Nil	
3	*		45	2 <sup>nd</sup> molar	Nil	*
4	*		50	1 <sup>st</sup> molar	Nil	
5		*	34	1 <sup>st</sup> premolar	Nil	
6		*	36	1 <sup>st</sup> molar	Nil	
7	*		38	1 <sup>st</sup> molar	Nil	
8	*		35	1 <sup>st</sup> molar	Nil	
9	*		40	1 <sup>st</sup> molar	Nil	
10	*		29	2 <sup>nd</sup> premolar	Nil	
11		*	45	2 <sup>nd</sup> molar	Nil	*
12		*	47	1 <sup>st</sup> molar	Nil	
13		*	35	2 <sup>nd</sup> premolar	Nil	
14		*	39	1 <sup>st</sup> molar	Nil	
15	*		41	2 <sup>nd</sup> premolar	Nil	
16	*		44	1 <sup>st</sup> molar	Nil	
17	*		43	1 <sup>st</sup> molar	Nil	
18	*		42	1 <sup>st</sup> molar	Nil	
19	*		31	2 <sup>nd</sup> molar	Nil	
20		*	51	1 <sup>st</sup> molar	Nil	
<b>Total: 20</b>	<b>13 (65%)</b>	<b>7 (35%)</b>	<b>Average 41 years</b>			<b>2 (10%)</b>



**Figure 10:** Showing the No. of implants, the sites, the success and failure rate



**Figure 11:** OPG radiograph of a patient with sinus lift after 3 months, there are signs of bone formation around the implant



**Figure 12:** OPG radiograph of a patient with sinus lift after 6 months showing complete bone formation around the implant

### Discussion

The goals of the sinus elevation procedure are the creation of vital bone in the posterior maxilla, the osseointegration of the implants placed in that bone and the survival of those implants under occlusal load.<sup>10</sup> The posterior maxilla may present an additional obstruction to implant placement due to pneumatization (increasing size) of the maxillary sinus. Some patients possess limited crestal bone height in the posterior maxilla even when teeth are present and it is not uncommon for the sinuses to pneumatize further after the extraction of the posterior teeth.<sup>14</sup>

According to some authors,<sup>11-13</sup> augmentation procedures are required when residual bone height beneath the sinus cavity is less than 8-10 mm. The American Academy of Periodontology (cited by Wallace)<sup>14</sup> stated that there is evidence to indicate that the lateral window technique for the sinus bone augmentation procedure is successful at regenerating sufficient bone for implant placement. The implant survival rate is greater than 90% which is similar to implants placed in native bone.

The evidence-based reviews further

identified some of the important variables that affect the outcome of this procedure. These variables are listed as follows:<sup>14,15</sup>

1. Particulate bone grafts result in a higher survival rate than block grafts.
2. bone replacement grafts result in a higher implant survival rate than autogenous bone or composite grafts
3. Rough surface implants result in a higher survival rate than machine-surfaced implants.
4. Membrane placement over the lateral window results in a higher implant survival rate than if a membrane is not used. In this study we reported a success rate of 90% which is similar to that reported by Tarnow et al<sup>16</sup> and Forum et al<sup>17</sup>. This high success rate could be attributed to the fact that xenograft has the following efficacy:
  1. osteoconductivity which enhance the direct apposition of vital bone on the xenograft surface.
  2. slow resorbability which both prevents slumping (loss of graft height) and adds approximately 25% to the overall mineral content of the matured graft.

3. The residual graft material does not interfere with osseointegration.<sup>7,14,18</sup>

On the other hand implants with rough surface texture was used, which is another factor that affects implant survival in sinus grafts. Rough surface implants result in a higher survival rate than machine-surfaced (smooth surface) implants because of the ability of rough surface to stabilize the blood clot and intimate bone formation.<sup>14</sup> In this study 2 (10%) cases were failed. It may be attributed to the fact that no membranes were used for all the patients (was not available) to cover the lateral window which isolate the area of regeneration and exclude non-osteogenic connective tissue from the graft site.<sup>14</sup>

## References

- Kahnberg KE, Ekestubbe A, Grondahl K, Nilsson P, Hirsch JM. Sinus lifting procedure. I. One-stage surgery with bone transplant and implants. *Clin Oral Impl Res* 2001; 12:479-87.
- Boyne PJ, James RA. Grafting of the maxillary sinus floor with autogenous marrow and bone. *J Oral Surg* 1980;38:613- 616
- Summers RB. A new concept in maxillary implant surgery: the osteotome technique. *Compend Contin Educ Dent* 1994;15:152-62.
- Zitzmann NU, Schäfer P. Sinus elevation procedures in the resorbed posterior maxilla. *Oral Surg Oral Med Oral Pathol Oral Radiol Endod* 1998; 85:8-17.
- Wetzel AC, Stich H, Caffesse RG. Bone apposition onto oral implants in the sinus area filled with different grafting materials. *Clin Oral Implants Res* 1995; 6:155-63.
- Hatano N, Shimizu Y, Ooya K. A clinical long-term radiographic evaluation of graft height changes after maxillary sinus floor augmentation with a 2:1 autogenous bone/xenograft mixture and simultaneous placement of dental implants. *Clin Oral Implants Res* 2004;15:339-45.
- Hallman M, Sennerby L, Zetterqvist L, Lundgren S. A 3-year prospective follow-up study of implant-supported fixed prostheses in patients subjected to maxillary sinus floor augmentation with an 80:20 mixture of deproteinized bovine bone and autogenous bone: clinical, radiographic and resonance frequency analysis. *Int J Oral Maxillofac Surg* 2005; 34:273-80.
- Dennis Smiler, Encino, CA. *Journal of Oral and Maxillofacial Surgery*, Volume 63, Issue 8, Supplement 1, August 2005, Page 138.
- Hürzeler M, Kirsch A, Achermann K, Quiñones C. Reconstruction of the severely resorbed maxilla with dental implants in the augmented maxillary sinus: A 5-year clinical investigation. *Int J Oral Maxillofac Implants* 1996; 11:466-475.
- Jensen OT, Shulman LB, Block MS, Iacone VJ. Report of the Sinus Consensus Conference of 1996. *Int J Oral Maxillofac Implants* 1998; 13:11-32.
- Schwarz-Arad D, Dolev E. The challenge of endosseous implants placed in the posterior partially edentulous maxilla: a clinical report. *Int J Oral Maxillofac Implants* 2000; 15:261-4.
- Toffler M. Osteotome-mediated sinus floor elevation: a clinical report. *Int J Oral Maxillofac Implants* 2004; 19:266-73.
- Wallace SS, Froum SJ. Effect of maxillary sinus augmentation on the survival of endosseous dental implants. A systematic review. *Ann Periodontol* 2003;8:328-343.
- Del Fabbro M, Testori T, Francetti L, Weinstein R. Systematic review of survival rates for implants placed in the grafted maxillary sinus. *Int J Periodontics Restorative Dent* 2004; 24: 565-578
- Tarnow DP, Wallace SS, Froum SJ. Histologic and clinical comparison of bilateral sinus floor elevations with and without barrier membrane placement in 12 patients: Part 3 of an ongoing prospective study. *Int J Periodontics Restorative Dent* 2000;20:116-125.
- Froum SJ, Tarnow DP, Wallace SS, Rohrer MD, Cho S-C. Sinus floor elevation using anorganic bovine bone matrix (OsteoGraf/N) with and without Autogenous bone: A clinical, histologic, radiographic, and histomorphometric analysis — Part 2 of an ongoing prospective study. *Int J Periodont Rest Dent* 1998;18:529-543.
- Hising P, Bolin A, Branting C. Reconstruction of severely resorbed alveolar crests with dental implants using a bovine mineral for augmentation. *Int J Oral Maxillofac Implants* 2001;16:90-97.
- Valentini P, Abensur D. Maxillary sinus floor elevation for implant placement with demineralized freeze-dried bone and bovine bone (Bio-Oss): A clinical study of 20 patients. *Int J Periodont Rest Dent* 1997;17:233-241.