

Incidence and in-hospital complications of acute mitral regurgitation in the early phase of acute myocardial infarction in Erbil teaching hospital

Received: 11/12/2010

Accepted: 7/9/2011

Firaz Muhammad Mawlood *

Abdulkareem A. Al-Othman**

Abstract

Background and objectives: Acute mitral regurgitation is one of the mechanical complications of acute myocardial infarction. The aim of the study was to detect the incidence of ischemic mitral regurgitation and its effect on in-hospital complications in early phase of acute myocardial infarction.

Method: The study sample consisted of 100 patients with first attack of acute myocardial infarction admitted to Coronary Care Unit in Erbil Teaching Hospital from October 2009 to May 2010. The patients categorized into: group-I which represent those without mitral regurgitation; group-II represent those with mitral regurgitation and the latter categorized patients with mild mitral regurgitation (group-IIA) and those with moderate-severe mitral regurgitation (group-IIB).

Results: The incidence of acute mitral regurgitation among patients with acute myocardial infarction was 33%. Fourteen patient (42.42%) had mild and 19 (57.58%) had moderate-severe mitral regurgitation. Group-II patients were older (mean age: 65.4 ± 10.76 years) than group-I (mean age 56 ± 11), p value=0.01. Left ventricular systolic dysfunction among group-IIA, 9 patients (64.28%) and group-IIB, 16 patients (84.21%) were higher than group -I, 12 patients (17.91%), $p < 0.001$.

Conclusion: Acute mitral regurgitation is common in early phase of acute myocardial infarction and it is strongly associated with left ventricular systolic dysfunction.

Keywords: Acute MI, MR.

Introduction

Ischemic mitral regurgitation is defined as mitral regurgitation (MR) caused by changes of left ventricular structure and function related ultimately to ischemia.¹ The mere presence of mitral regurgitation (MR) after acute MI has been shown to adversely affect prognosis.^{2,3} Severe MR complicating (AMI) is an important cause of hemodynamic instability and cardiogenic shock (CS).^{4,5} The clinician cannot rely on a new holosystolic murmur to diagnose MR or assess its severity because of the variable hemodynamic status. In a patient with AMI who presents with a new apical systolic murmur, acute pulmonary edema, and CS, a high index of clinical suspicion

for severe MR is the key to diagnosis.⁶ Transthoracic echocardiography is the most general useful non invasive test obtained on admission or early in-hospital course and enables the clinician to evaluate suspected complications of AMI.⁷ The aim of the study is to detect the incidence of ischemic mitral regurgitation and its effect on in-hospital complications in early phase of acute myocardial infarction.

Method

A descriptive case review study was done on cases of AMI attending the CCU at Erbil Teaching Hospital from October 2009 to May 2010. Patients with first attack of AMI (both ST-segment elevation myocardial infarction and non- ST-segment elevation

*Department of Medicine, Hawler Teaching hospital, Erbil-iraq.

**Department of Medicine, College of Medicine, Hawler Medical University, Erbil-Iraq.

myocardial infarction) of both sexes and all age groups whose duration of chest pain from its onset till admission to CCU is less than 24 hours was included in the study with exclusion of those with history of previous AMI, left bundle branch block, previous history of valvular heart disease, rheumatic heart disease heart failure and renal failure. Diagnosis of acute MR was made depending on WHO criteria formulated in 1979 and refined in 2000 according to which a cardiac troponin rise accompanied by either typical symptoms, pathological Q waves, ST segment elevation or depression or coronary intervention are diagnostic of AMI. In-hospital complications like arrhythmias including (Ventricular fibrillation, Ventricular tachycardia, Heart block, atrial fibrillation and ventricular ectopic beats), pulmonary edema, cardiogenic shock and in-Hospital death were recorded. Two dimensional transthoracic color Doppler echocardiography was performed for patients within first 5-7 days of admission to the CCU using 2.5MHZ transducer, Philips(Envois, version 1-A,2003). Left ventricular ejection fraction (EF) was determined from apical and four chamber view using the Simpson's biplane formula. Left ventricular systolic dysfunction (LVSD) in patients without MR defined as left ventricular EF is $\leq 50\%$.⁹ LVSD in the presence of acute MR was diagnosed when the EF is $\leq 60\%$.^{10,11} Two dimensional echocardiography parameters used for the diagnosis of MR and for the assessment of its severity, a- Color Doppler study – Vena contracta < 3 mm considered as mild MR, Vena contracta > 6 mm considered as severe MR. b- Spectral Doppler density – Faint Doppler density considered as mild, Dense Doppler density considered as severe MR.¹² Patients with AMI were classified according to the absence (group-I) or presence (group-II) of acute MR diagnosed by 2-D Color Doppler echocardiography. Patients with mild MR were labeled group-II A and those with severe MR were labeled group-II B.

Statistical analysis: Statistical Package for Social Sciences (SPSS) used for data analysis using t test used for continuous variables and chi square test for categorical variables. P value < 0.05 was regarded significant.

Results

A clinically audible MR was present in 7 patients (7%); in contrast MR detected by 2-D echocardiography (Figure 1,3) was present in 33 patients (33%). Table (1) The incidence of male sex in group-II, 19 patients (57.58%) was higher than female sex, 14 patients (42.42%) but without significance p value =0.057. Group-II patients had a higher mean age (65.4 ± 10.76 years) than Group-I patients (56 ± 11 years), P value of 0.01. The risk factors which include hypertension, diabetes mellitus, smoking, family history, hyperlipidemia, and obesity are studied and there was no statistically significant difference in both groups of patients as shown in Table (2). Anterior MI was recorded in 58% of patients and 42% had inferior wall MI. The incidence of AMR diagnosed by 2-D echocardiography was higher among patients with anterior MI, 22 patients (37.9%) as compared with inferior MI, 11 patients (26.2%) but without statistically significant values, Table (3). Different types of arrhythmias were present in those patients suffered from AMI, the incidence was compared between the two groups and there was no significant statistical difference between them, Table (4). Among patients with group II one patient (3%) presented with pulmonary edema and 2 patients (6%) with cardiogenic shock. In group –I three patients (4.5%) presented with pulmonary edema and 2 patients (3%) with cardiogenic shock which means that cardiogenic shock is two times more common in patients with MR, but without statistical significant p value. Mild MR (group-II A) detected by 2-D echocardiography in the first week of AMI was present in 14 patients (42.42%) as compared with 19 patients (57.58%)

having moderate-severe MR (group-II B). Group- II A patients had a higher incidence of LVSD, 9 patients (64.28%) as compared with group-I patients,12 patients (17.91%), p value = 0.00. as seen in Table (5). Left ventricular regional wall abnormalitie (RWA) was higher among group-II A (7 patients, 50%) as compared with group-I (29patient, 43.28%), but without statistically significant value (Table 5), (Figure 9). Group-II B patients had a higher frequency rate of LVSD ,16 patients(84.21%) as compared with group-I,12 patients (17.9%). P value = 0.00, as shown in (Table 6). Also they had a higher frequency rate of RWA, 9 patients (47.36%) as compared with group-I, 29 patients (43.28%), but without significant value (p= 0.75), Table (6).

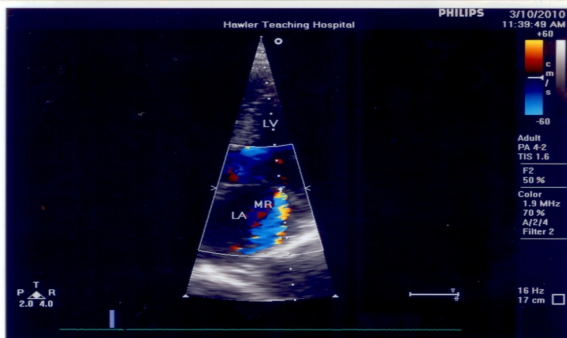


Figure 1: Apical four chamber view recorded from a patient with lateral mitral regurgitation. LV=left ventricle, MR=mitral regurgitation, LA= left atrium.

Table 1: Mitral regurgitation diagnosed by 2-D echocardiography and cardiac Physical examination.

MR detected by 2 D-echo.		MR detected by auscultation		P value
N	%	N	%	
33	33	7	7	0.00*

MR = mitral regurgitation.
P value is significant.

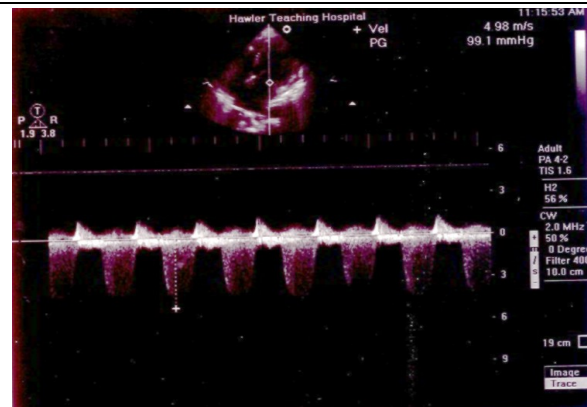


Figure 2: Continuous Wave Doppler recording from a patient with severe MR. **Note** the dense signal density, PG=99mmHg, velocity=4.98m/s.

Table 2: Distribution of risk factors in both groups of patients.

Risk factors	Group-I n=67	Group-II n=33	P value
Hypertension n (%)	33 (49.25)	17(51.5)	0.83
DM n (%)	15(22.4)	7(21.21)	0.89
Smoking n (%)	45(67.17)	19 (57.57)	0.34
Family history of IHD n (%)	14(20.9)	9(27.3)	0.47
Hyperlipidemia n(%)	8(11.94)	7(21.21)	0.22
BMI ≥ 30 n (%)	3(4.47)	1(3)	0.71

Group-I = patients with mitral regurgitation, Group-II = patients without Mitral regurgitation
DM=diabetes mellitus, IHD=ischemic heart disease, BMI=body mass index.

Table 4: Comparison of the incidence of arrhythmias between group I&II.

Type of Arrhythmia	Group-I n = 67	Group-II n = 33	P value
VF n(%)	7 (10)	2 (6)	0.47
AF n(%)	2 (3)	3 (9)	0.32
VEB n(%)	4 (6)	1 (3)	1

Group-I = patients without mitral regurgitation,

Group-II = patients with Mitral regurgitation,

VF = ventricular fibrillation,

AF = atrial fibrillation,

VEB = ventricular ectopic beats.

Table 5: Incidence of LVSD and left ventricular regional wall abnormality between group-I and group-IIA.

complication	Group-I n = 67	Group-IIA n =14	P value
LVSD n(%)	12(17.91)	9(64.28)	0.00*
LV-RWA n(%)	29(43.28)	7(50)	0.6

Group-I = patients without mitral regurgitation,

Group-II A = patients with mild mitral regurgitation,

LVSD= left ventricular systolic dysfunction,

LV-RWA= left ventricular regional wall abnormality. p value is significant.

Table 6: Comparison of incidence of left ventricular systolic dysfunction and left ventricular regional wall abnormality between group-I and group-IIB.

Complications	Group-I n = 67	Group-IIB n = 19	P value
LVSD n (%)	12(17.91)	16 (84.21)	0.00*
LV-RWA n(%)	29(43.28)	9 (47.36)	0.75

Group-I =patients without mitral regurgitation, group-II B =patients with moderate-severe mitral regurgitation.

LVSD = left ventricular systolic dysfunction,

LV- RWA = left ventricular regional wall abnormality. *p value is significant.

Discussion

The incidence of AMR described in this study was lower than that seen in another study done by Kono T. *et al* and Barzilai B. *et al* the incidence of MR was 39% in patients presented with MI.^{13,14} while in an other study done by Lamas who studied 727 patient, MR detected by LV angiogram was present in 141 patient i.e. 19.4%.¹⁵ also a study done by Lehman *et al* who studied 206 patients with first MI, the incidence of AMR was 13%.¹⁶ Mitral regurgitation when present, it may exhibit a broad range of severity, from clinically evident and hemodynamically obvious to clinically silent and detected only as an incidental finding on catheterization or Doppler echocardiography.¹⁷ This supports our results in which among the cases of AMR diagnosed by echocardiography examination only a small number of them had audible murmur of MR by physical examination. Patients who experienced AMR were more likely male and older, in contrary to the results of the study done by Lamas *et al* in which the females were more and older than males.¹⁶ Also in a study done by Francesco G. *et al* the mean age of those with MR was also more than the mean age of those without MR¹⁸, which is similar to our study. No association was found between the presence of MR and the presence of co morbidities like hypertension or diabetes mellitus in contrast to the results of a study done by Francesca *et al* in which there was positive graded association between the presence of MR and the presence of hypertension and diabetes¹⁹, in the same study done by Francesca *et al* there was no association of MR with smoking, hyperlipidemia, family history of IHD and obesity which consistent with our results. The incidence of AMR diagnosed by 2 D echocardiography was higher among patients with acute anterior MI as compared to patients with acute inferior MI but without statistically significant p value which is similar to the study done by Lehmann *et al* who described it as

chiefly associated with anterior MI¹⁶, in contrast to a study done by F.E. Calvo *et al* which shows that AMR is mostly related to inferior infarction and of single vessel disease²⁰, in contrast Tchong *et al* reported that 18% of patients without MR and 33% of patients with MR had three-vessel coronary artery disease⁷, also a study done by Kono T. *et al* and Barzilai B. *et al* They found that MR is a more common complication of inferior than anterior MI^{18,19}, and other studies revealed no association of MR with location of the infarction.^{17,21} Cardiogenic shock can be caused by large left ventricular infarction, severe right ventricular infarction, ventricular septal rupture, free wall rupture, AMR or pharmacological depression of left ventricle.²² This can explain our results in which cardiogenic shock although present in a small percentage in cases of MR but still two times more than in those without MR. In an other study AMR was considered a potential cause of pulmonary edema.^{23,24} The percentage of moderate-severe MR was higher than those with mild MR in contrast to the results found by Feinberg *et al* who demonstrated 29% mild MR and 6% moderate-severe MR out of 417 patient assessed by echocardiography.²¹ Tchong *et al* reported that patients with no MR, mild MR and severe MR had a stepwise increase in overall mortality.³ Mittal *et al* speculated that papillary muscle dysfunction alone is insufficient to cause MR after MI and that an underlying wall motion abnormality is needed.²⁵ This supports our results with the presence of RWA in the patients with MR and it has been claimed that extensive involvement of the area of implantation of the mitral apparatus is necessary for MR to be severe.²⁶ However Kaul *et al* claimed that in dogs MR is more closely related to impairment of left ventricular function than to the degree of regional dyskinesia or papillary muscle dysfunction²⁷ which is consistent with our results.

Conclusion

The incidence of acute MR diagnosed by 2D- echocardiography in the early phase of AMI is high, often clinically silent. Acute MR is strongly associated with high incidence of LVSD in the early phase of AMI.

Recommendations

Echocardiography is recommended for those patients in the early phase of AMI for earliest detection of acute MR and LVSD. The assessment of MR should be included in post MI risk stratification.

Study limitations: Absence of catheterization laboratory in our center to assess the extent of coronary artery disease in those patients with acute MR. Our echocardiographic findings were observed after AMI and do not exclude that some MR was present beforehand in some patients.

References

1. Thomas H, Patrizio L, Luc P. Ischemic mitral regurgitation: mechanisms and Diagnosis. *Heart* 2009;95:1711-1718.
2. Eisenberg PR, Barzilai B, Perez JE, Non-invasive detection by Doppler echocardiography of combined ventricular septal rupture and mitral regurgitation in acute myocardial infarction. *J Am Coll Cardiol.*1984;4:617- 20.
3. De Servi S, Vaccari L, Assandri J. Clinical significance of mitral regurgitation in patients with recent myocardial infarction. *Eur Heart J.*1988;9:5-9.
4. Tchong JE, Jackman JD Jr, Nelson CL, et al. Outcome of patient sustaining acute ischemic mitral regurgitation during myocardial infarction. *Ann Intern Med.*1992;117(1):18 –24.
5. Bolooki H. Emergency cardiac procedures in patients in cardiogeni shock due to complications of coronary artery disease. *Circulation* 1989; 79:1137 – 48.—etiologies, management and outcome: a report from the SHOCK Trial Registry. *J Am Coll Cardiol.* 2000; 36:1063–70
6. Rosamond W, Flegal K, Friday G. Heart disease and Stroke statistics- 2007 update: a report from the American Heart Committee and Stroke Statistics Subcommittee. *Circulation.*2007; 115:69- 171.
7. Anderson JL. ST segment acute myocardial infarction and complications of myocardial infarction. In: Goldman Land Ausiello D, (eds). *Cecil Textbook of Medicine.* 23rd Edition. USA.SAUNDERS ELSEVIER.2007.p.508.
8. Elliot A, Jean-Pierre B, Werner O, Jose L, Lopez S, Lars R et al . Myocardial Infarction redefined. *J Am Coll Cardiol.*2000; 36:959-969.

9. Ramadas G, Pal and Pravin M. Shah. Assessment of left ventricular Function. In: Gerald M, Pohost A.O, Daniels B, Pravin M.,(eds)Imaging in Cardiovascular Diseases. First ed. Lippincott Williams and Wilkins .2000;p. 23-41.
10. Enriquez- Saramo M, Schaff HV, Tajik AJ. Chronic mitral Regurgitation. In: Alpert JS, Dalen JE, Rahimtoala SH (eds): Valvular Heart Disease. 3rd ed. Philadelphia. Lippincott Williams and Wilkins.2000; p. 113-142.
11. Matsumura T, Ohtaki E, Tanaka K. Echocardiographic predictors of Left ventricular dysfunction after mitral valve repair for mitral regurgitation as an indicator to decide the optimal timing of repair. J Am Cardiol.2003; 42:458.
12. Feigenbaum H,Armstrong WF, Ryan T. Coronary Artery Disease. Feigenbaum's Echocardiography, 6th Edition,Lippincott Williams and Wilkins Company,2005.p.306-469.
13. Kono T, Sabbah HN, Rosman H, Alam M, Jafri S, Stein PD, Goldstein S. Mechanism of functional mitral regurgitation during acute myocardial Ischemia. J Am Coll Cardiol.1992;19:1101-1105.
14. Barzilai B, Davis VG, Stone PH, Jaffe AS. Prognostic significance of mitral regurgitation in acute myocardial infarction. Am J Cardiol.1990; 65:1169-1175.
15. Lamas GA, Mitchell GF, Flaker GC, Smith SC Jr, Gresh BJ, Basta L et al. Clinical significance of mitral regurgitation after acute myocardial infarction. Circulation 1997; 96:827-833.
16. Lehmann KG, Francis CK, Dodge HT. Mitral regurgitation in early myocardial infarction. Incidence, clinical detection, and prognostic implications. TIMI Study Group. Ann Intern Med. 1992; 117:10-17.
17. Barzilai B, Gessler C, Perez JE, Schaab C, Jaffe AS. Significance of Doppler detected mitral regurgitation in acute myocardial infarction. Am J Cardiol.1988;61:220-223.
18. Francesco G. Ischemic Mitral Regurgitation. Circulation. 2001; 103:1759-19. Francesca B, Maurice ES, Vuyisile TN, Steven JJ, Susan AW, Ryan M et al. Heart failure and Death After Myocardial Infarction in the community: The Emerging Role of Mitral regurgitation. Circulation.2005;111:295-301.
20. Calvo F.E. Mitral regurgitation complicating AMI. European Heart Journal.1997;18:1606-1610.
21. Feinberg MS, Schwammenthal E, Shlizerman L. Prognostic Significance of mild mitral regurgitation by color Doppler echocardiography in acute myocardial infarction. Am J Cardiol. 2000;86:903-907.
22. Wei JY. Hutchins GM, Bulkley BH. Papillary muscle rupture in fatal acute myocardial infarction. Ann Intern Med.1979;90:149-152.
23. Otsuji Y, Handschumacher MD, Schwammenthal E. Insights from three dimensional echocardiography into the mechanism of functional mitral regurgitation: direct in vivo demonstration of altered leaflet tethering geometry. Circulation .1997; 96 :1999-2008.
24. Hung J, Otsuji Y, Schwammenthal E, Levine RA. Mechanism of dynamic regurgitant Handschumacher orifice area variation in functional mitral regurgitation: physiologic insights from the proximal flow convergence technique.J Am Coll Cardiol. 1999; 33:538-545.
25. Mittal AK, Langston M, Cohn KE, Seizer A, Kerth W. Combined papillary muscle and left ventricular wall dysfunction as a cause of mitral regurgitation: an experimental study. Circulation.1971;44:174-180.
26. Llaneras MR, Nance ML, Streicher JT .Large animal model of ischemic mitral regurgitation. Ann Thora Surg. 1994; 57:432-441.
27. Kaul S, Spotnitz WD, Glasheen WP, Touchstone DA. Mechanism of Ischemic mitral regurgitation An experimental evaluation. Circulation. 1991 ;84:2167-2274.